



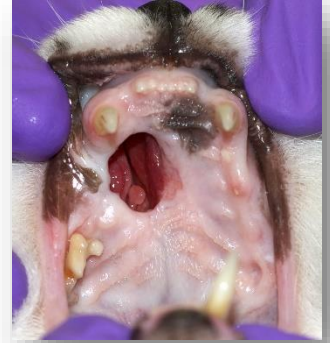Ossiflex Bone Membrane Closes Champ's Large Palatal Defect



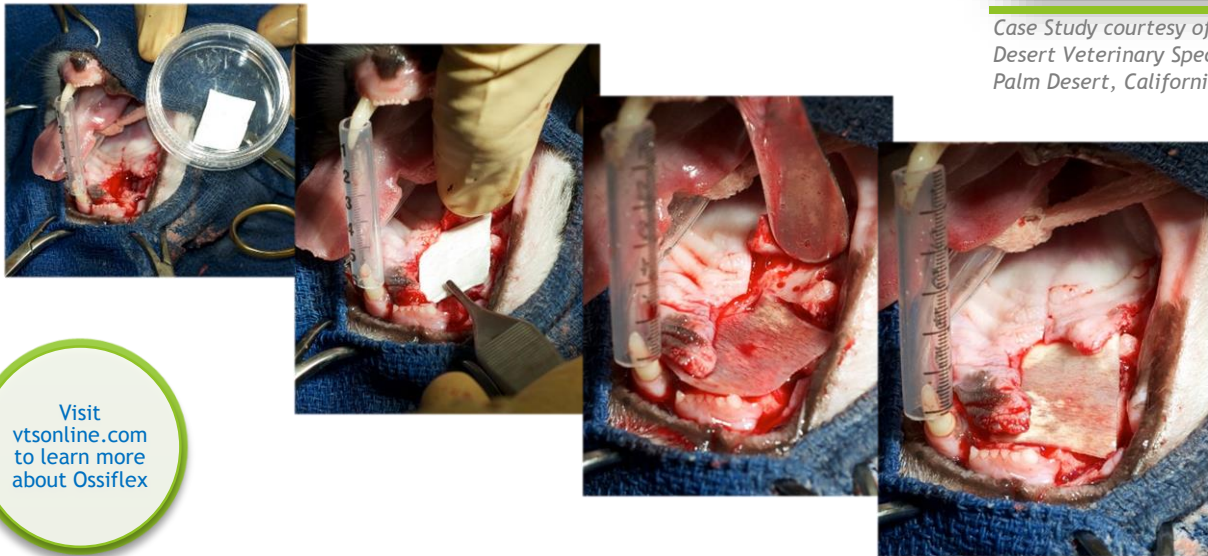
Closure of a healed opening in a feline palate

Even though Champ had a large, healed opening in his palate, he was adopted from a shelter by 92 yr old Walter and his wife. Champ was a patient cat, submitting to weekly trips to the vet for sinus lavage but these became more and more difficult for his elderly owner. Champ was referred to Dr. Judy Yee of Desert Veterinary Specialists in Palm Desert, CA for closure of this healed open palate defect.

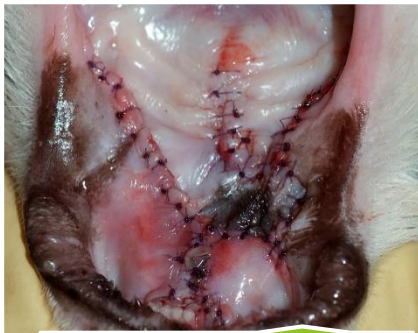Dr. Yee used an Ossiflex Bone Membrane to cover the large opening in Champ's palate. The mucosal layer closed over the membrane and Champ healed well, as can be seen in the follow up photos. Champ eats well and is back to a normal life.



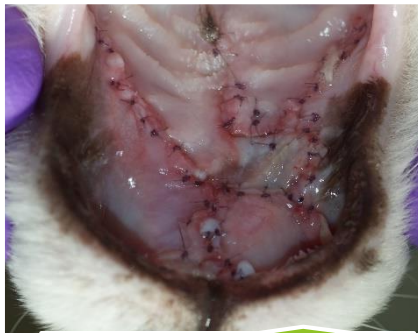Case Study courtesy of Dr. Judy Yee,
Desert Veterinary Specialists
Palm Desert, California



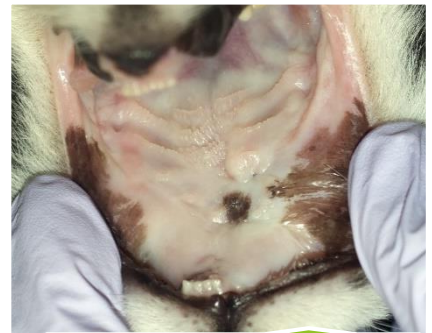Visit
vtsonline.com
to learn more
about Ossiflex



Immediate Post-Op



1 Week Follow-Up



1 Yr 5 Mos Follow-Up

Ossiflex is a thin, flexible sheet of natural demineralized cortical bone that effectively closes palatal and other cranio-maxilo-facial defects.