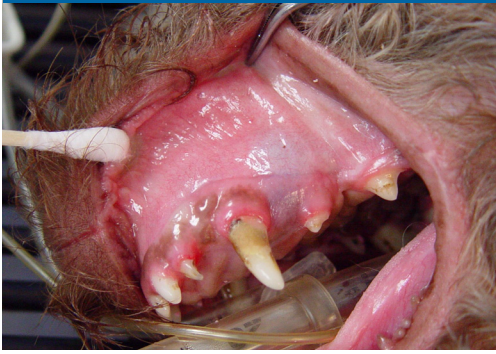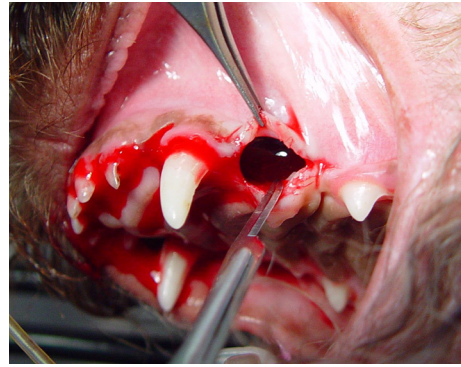


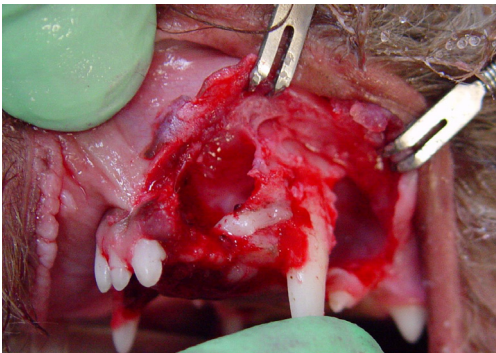


Invisible from the outside, this dog presented with a maxillary cyst that is destroying the facial bones that support the nasal cavities (fossae).

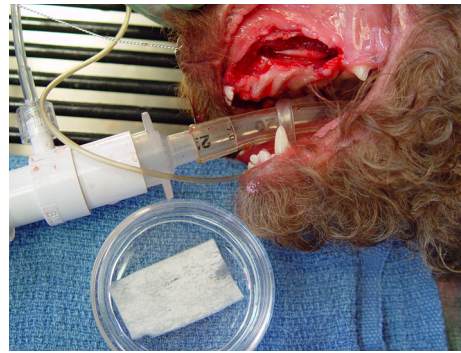

Incision into the soft tissue slowly exposes the cyst.

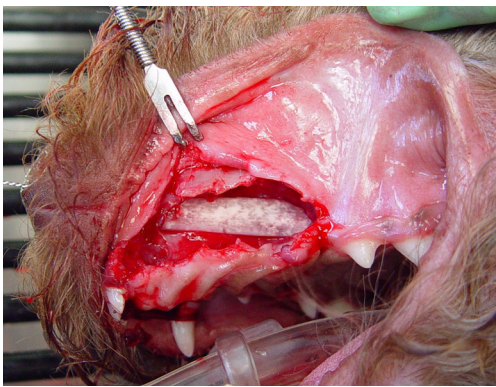
Annie  
5 y/o  
Toy  
Poodle



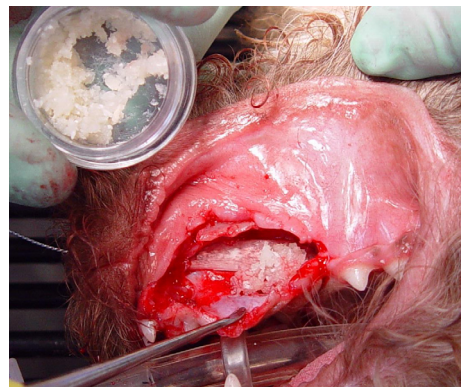
The destructive nature of the maxillary cyst is fully exposed.



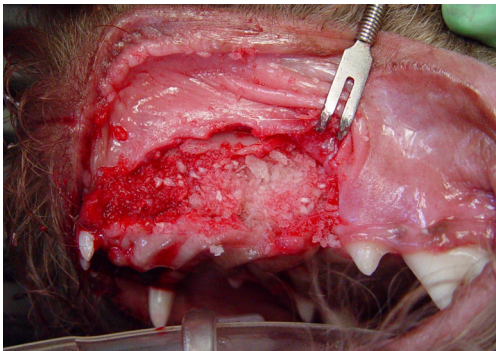
A freeze-dried **Ossiflex® Bone Membrane** is rehydrated with saline. A sterile swab is placed into the nasal fossa to guide the membrane placement.



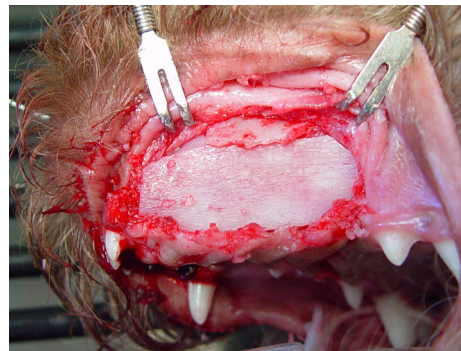
The **Ossiflex® Bone Membrane** is secured to protect the ventral nasal meatus.



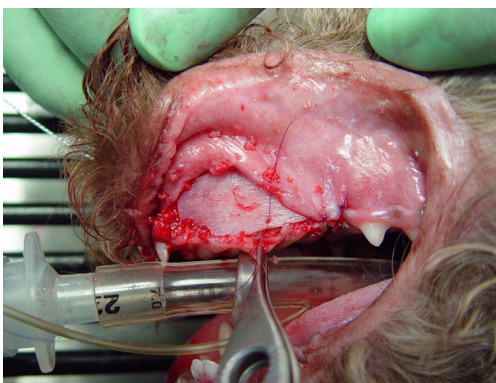
**Osteoallograft® Periomix®** is applied into the defect as a graft to rebuild the hard palate, alveolar, and incisive bone.



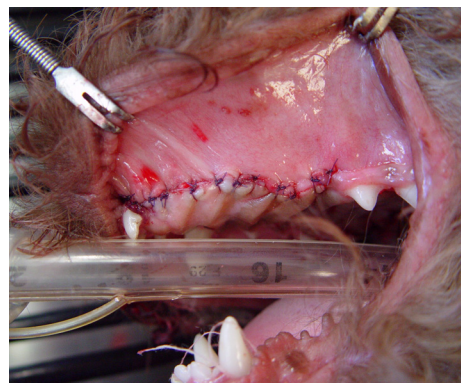
The defect is completely filled with **Osteoallograft® Periomix®** to achieve maximal bone regeneration.



For Guided Bone Regeneration, the particulate bone graft is covered with an **Ossiflex® Bone Membrane** to avoid premature in-growth of soft tissue.

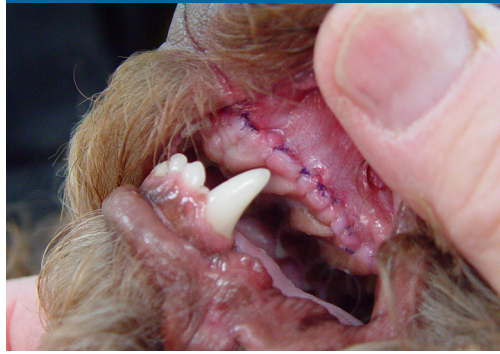

The bone membrane is sutured in place and soft tissue is sutured closed.

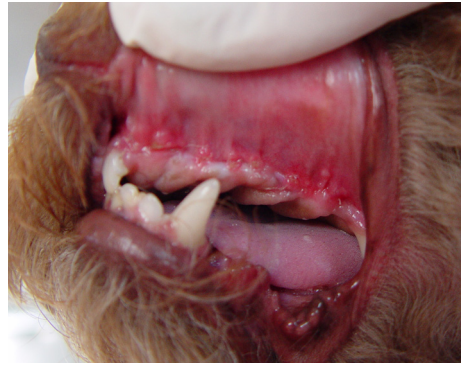

Sutures are in place and the surgery is complete.

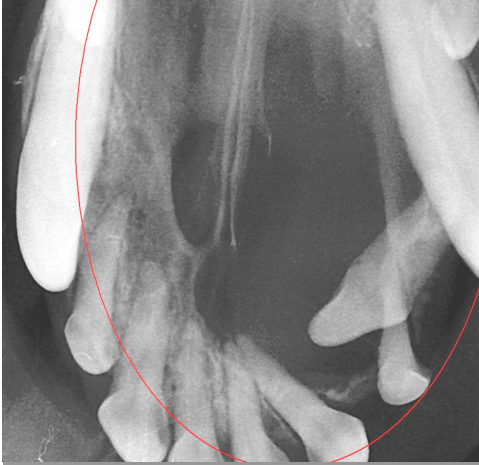Images courtesy of Rocco Mele, DVM



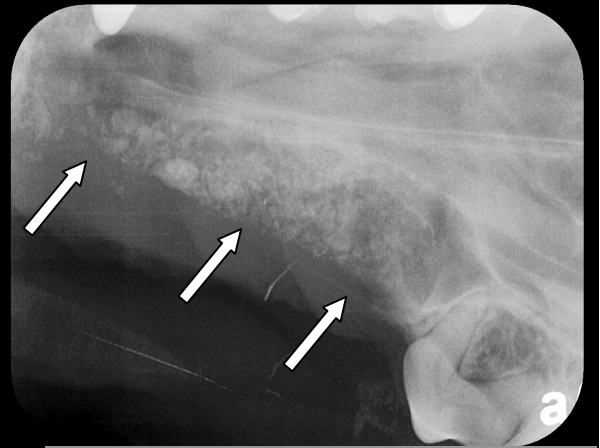
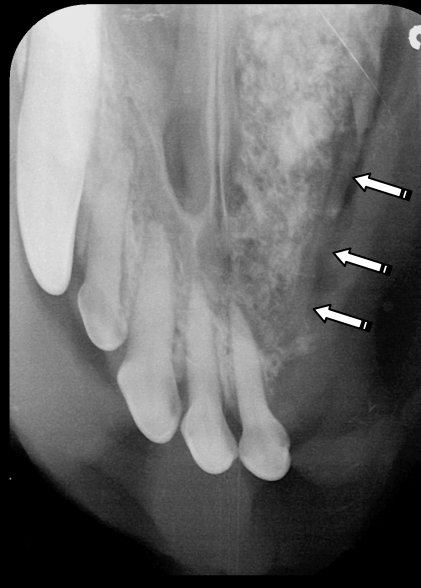
**3 DAY POST OP:**  
At a 3-day follow-up visit, the surgical site remains in good condition.



**6 WEEK POST OP:**  
Site appears nicely healed and maxillary bone is palpably solid.



**PRE OP:**  
The occlusal radiograph shows the size and scope of the cyst.

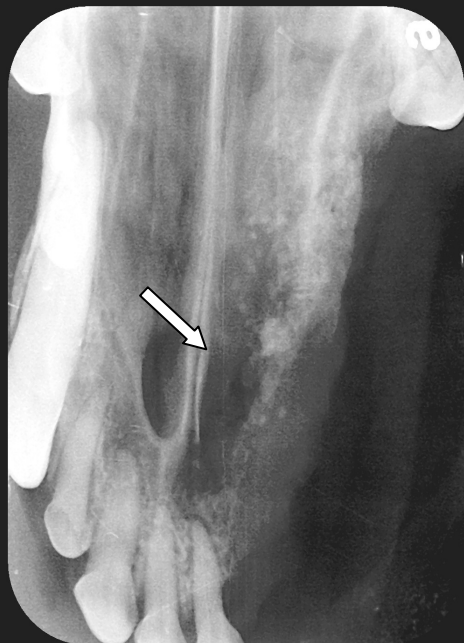

**POST OP:**  
The particulate graft is retained by the demineralized Ossiflex Membrane (arrows).

**6 WEEK FOLLOW UP:**

At 6 weeks, the Palatine Fossa is slowly becoming visible (arrow). Ossiflex is still functioning to retain the mineralizing Periomix.

Architectural remodeling and new bone around incisors is evident.



**6 MONTH FOLLOW UP:**

The six month follow-up radiograph shows that the bone is regenerating to form the structural foundation of the Palatine fossa.

The dog is breathing normally.

