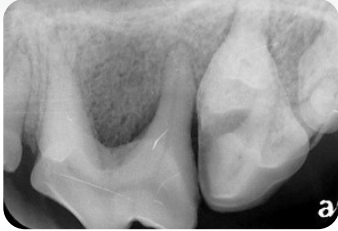

## VTS SYNERGY™

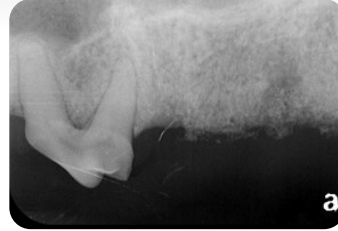### RUDY 8 Year Old Scottish Terrier



PRE-OP



IMMEDIATE POST -OP



1 MONTH FOLLOW UP

#### 100% SYNERGY

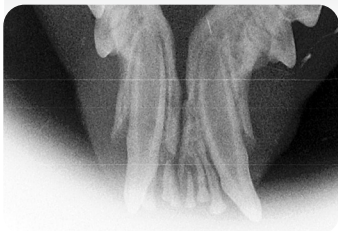#### DX & PROCEDURE:

Ulcerative Parodontal Stomatitis. Note deep pocket at distal root of 4th premolar, requiring extraction of premolar and molars. Extraction sites filled with 100% VTS SYNERGY.

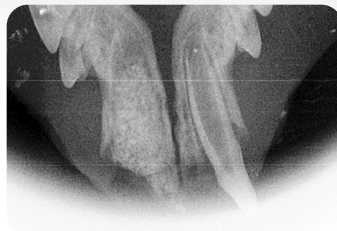#### OBSERVATION:

Bone of excellent quality, no vertical bone loss, maintenance of interproximal bone.

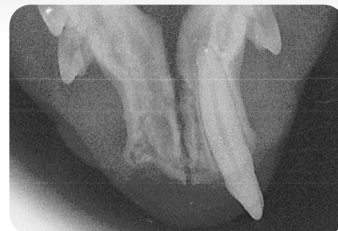### BONGO 2 Year Old Siamese



PRE-OP



IMMEDIATE POST -OP



1 YEAR FOLLOW UP

#### 100% SYNERGY

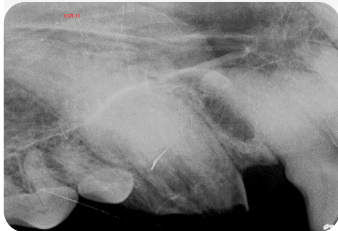
#### DX & PROCEDURE:

Feline stomatitis involving right mandibular canine and incisors. Extraction site filled with 100% SYNERGY.

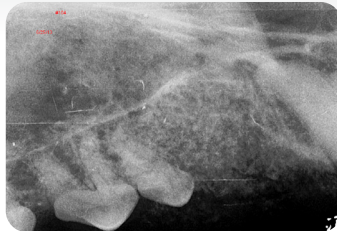
#### OBSERVATION:

Good bone fill, minimal bone loss. Good mandibular stability.

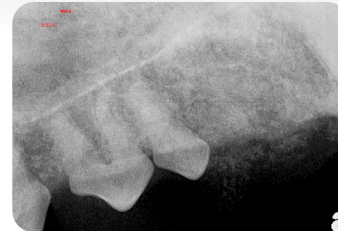### INDIA 6 Year Old Shar-Pei



PRE-OP



IMMEDIATE POST -OP



3 MONTH FOLLOW UP

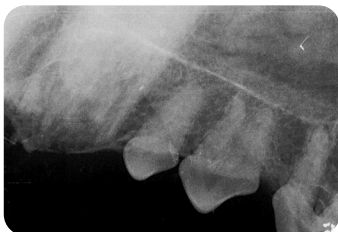#### 25:75 SYNERGY + XENOGRAFT

#### DX & PROCEDURE:

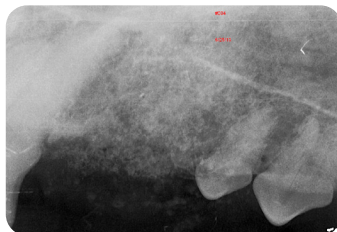
Canines fractured secondary to internal root resorption; (patient affected by Sharpei fever). Canines extracted and sites filled with VTS SYNERGY and xenograft (VTS Orthomix equine), 25:75 mixture, covered with VTS OSSIFLEX Membrane.

#### OBSERVATION:

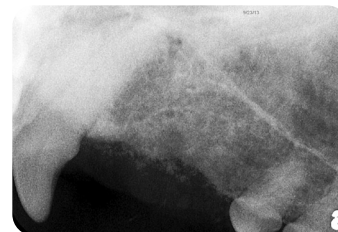Good bone response. Evidence of remodeling seen at 3 months.



PRE-OP



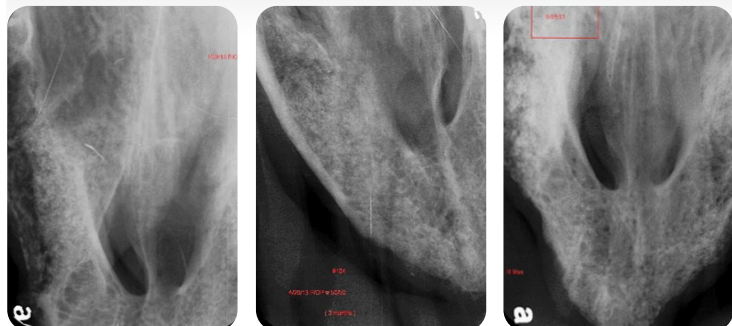
IMMEDIATE POST -OP



3 MONTH FOLLOW UP

## VTS SYNERGY™

### ROXY 12 Year Old Greyhound



IMMEDIATE POST      3 MONTH FOLLOW UP      7 MONTH FOLLOW UP

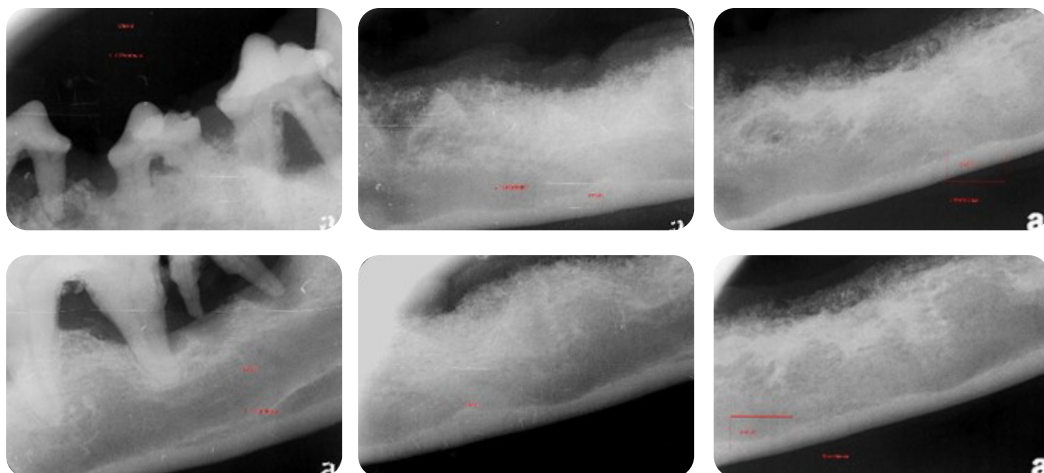
#### 50:50 SYNERGY + XENOGRAFT

##### DX & PROCEDURE:

Severe, advanced periodontal disease requiring full mouth extraction. Extraction sites filled with VTS SYNERGY and xenograft (VTS Orthomix equine), 50:50 mixture.

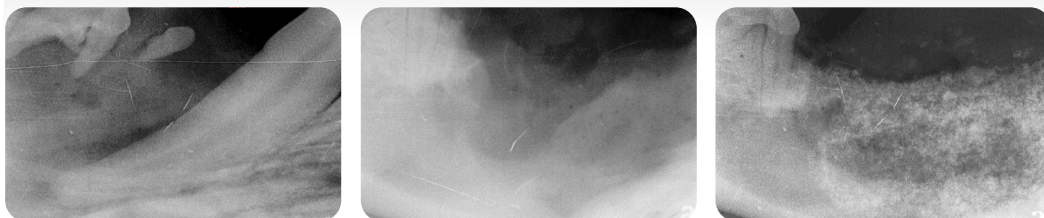##### OBSERVATION:

At 3 months, VTS SYNERGY/xenograft mixture has healed in well. Follow up at 7 months shows continued remodeling and maintenance of bone height. Dense cortical bone evident on superior margin of mandible.

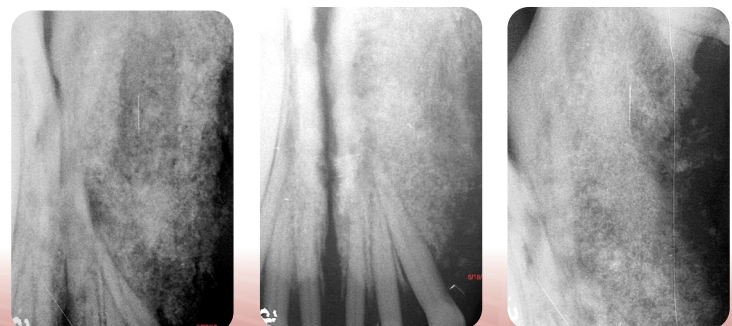


PRE-OP      IMMEDIATE POST      7 MONTH FOLLOW UP

### CARLOS 2.5 Year Old Boxer



PRE-OP      EXTRACTION SITE      IMMEDIATE POST



IMMEDIATE POST      3 MONTH FOLLOW UP

#### 100% SYNERGY + DEMIN BLOCK

##### DX & PROCEDURE:

Dentigerous cyst. Extraction sites filled with VTS PRESSFIT Block and VTS SYNERGY.

##### OBSERVATION:

The outline of the PRESSFIT block is visible, surrounded by VTS SYNERGY in the immediate post-op image. At 3 mos there is excellent bone remodeling. VTS PRESSFIT block re-mineralizing nicely.

Case studies courtesy of Dr. Rocco Mele