



## C A S E S T U D Y D E T A I L S

PATIENT NAME: Juaquin

WEIGHT: 5 lbs.

AGE/SEX: 6y / Male

BREED: Chihuahua

CONDITION: Previous amputee with a resorptive non-union in the remaining forelimb.

TREATMENT: Replacement and augmentation with surface demineralized allograft ribs and demineralized powder.

SURGEON: Dr. Ken Greenwood

CLINIC: Northlake Veterinary Specialists

LOCATION: Clarkston, GA

TYPE OF GRAFT USED:

- Osteo-Allograft™ Demineralized Bone Powder
- Custom Canine Rib Allografts

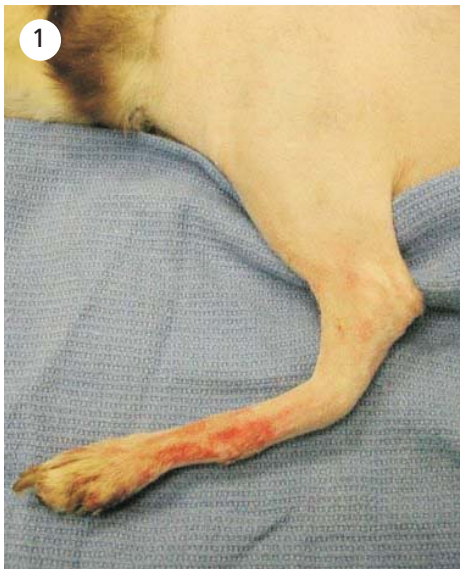

FIGURE 1: Pre-op photo showing limb deformity.

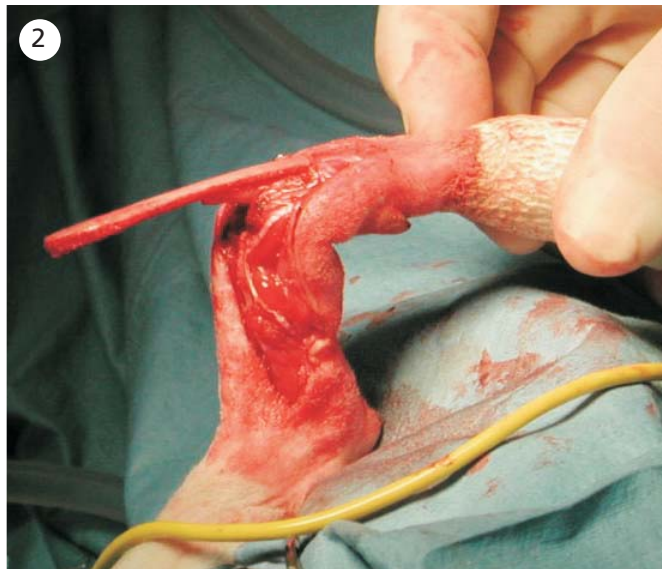


FIGURE 2: The rib allograft is secured distally.

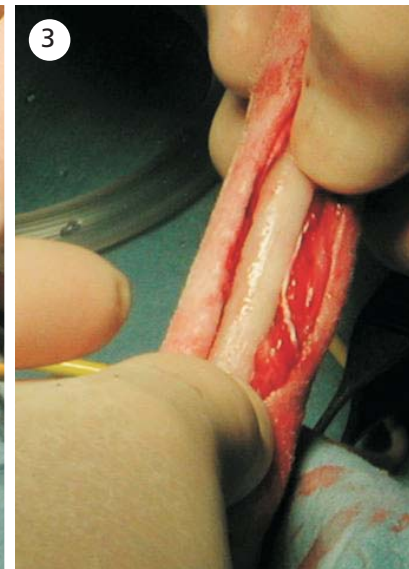


FIGURE 3: Alignment is made before securing with screws.

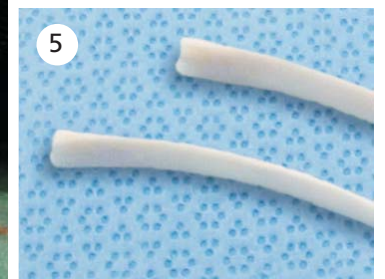
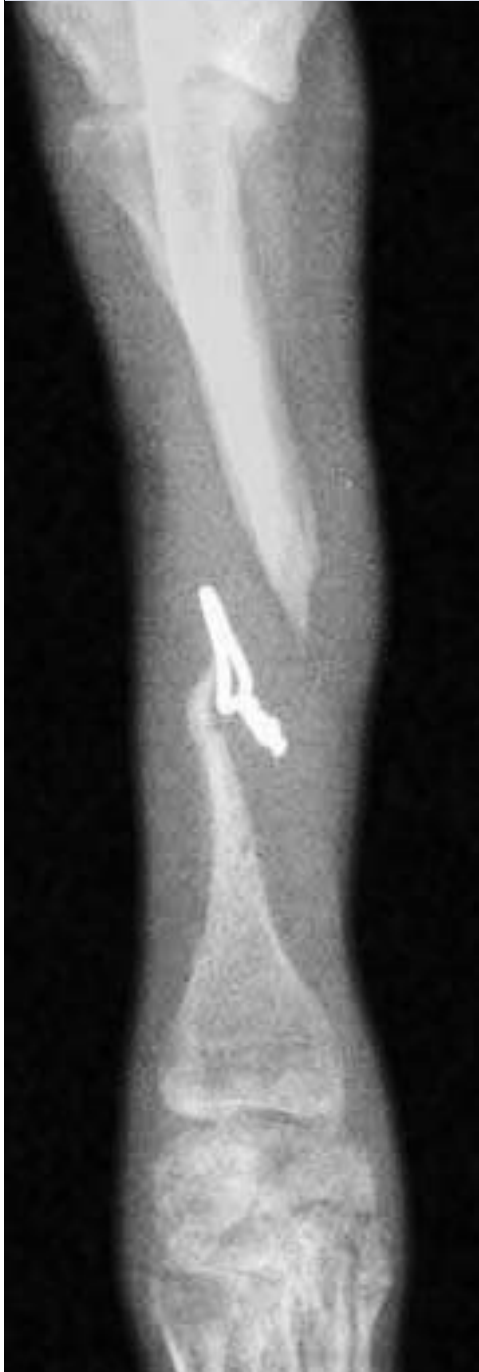
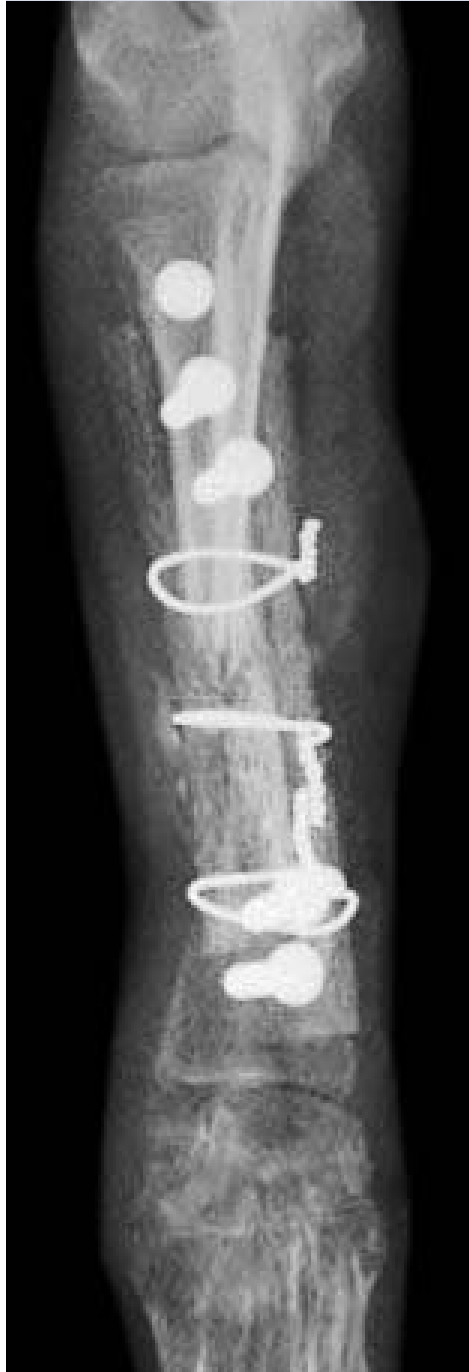
FIGURE 4: Demineralized Powder  
FIGURE 5: Rib Allografts

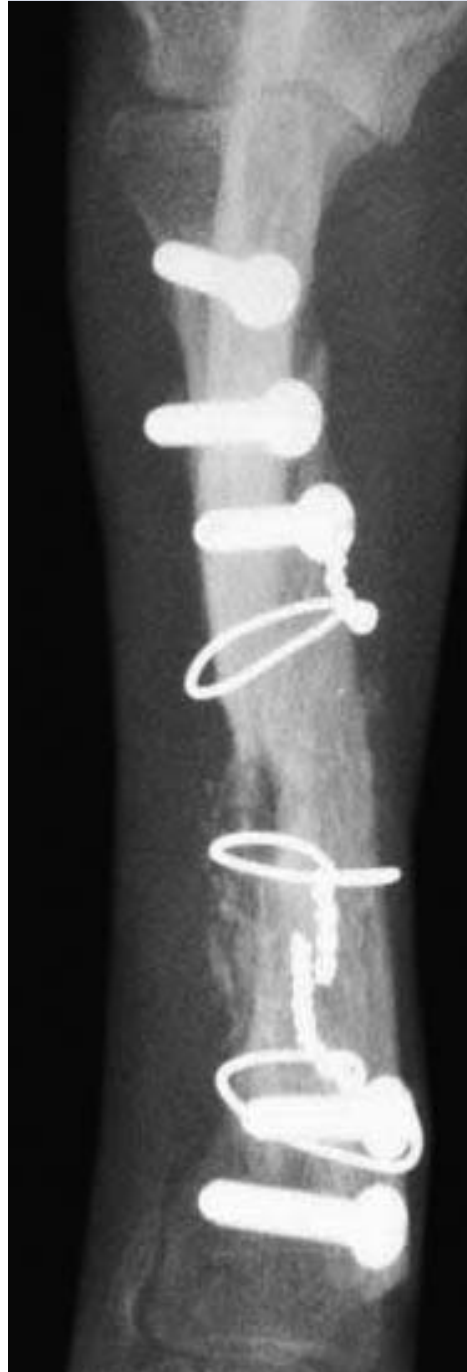PRE-OP AP



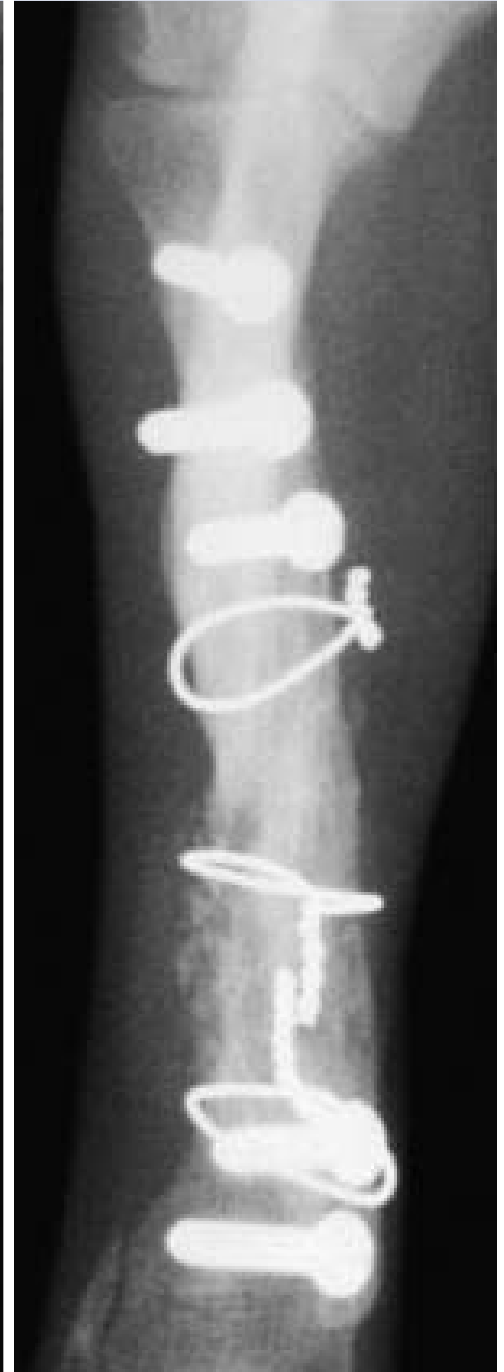POST-OP AP



POST-OP AP AT 3 MONTHS



POST-OP AP AT 6 MONTHS



PATIENT NAME: Juaquin  
AGE/SEX: 6y / Male

WEIGHT: 5 lbs.  
BREED: Chihuahua

Bone grafts for this case study provided by Veterinary Transplant Services. For more information about transplant tissues, please call VTS at 1-800-558-5223 or on the Web at [www.VTsonline.com](http://www.VTsonline.com).

